

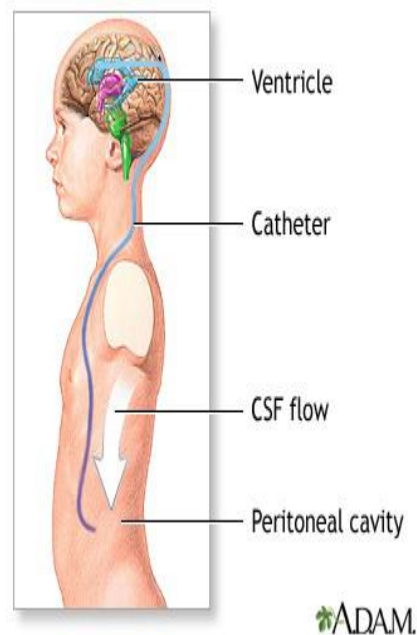


Overview of Shunts and Their Potential Hazards December 8, 2015

Why are shunts needed? Shunts are needed primarily for the treatment for hydrocephalus.

What is hydrocephalus? Hydrocephalus is a buildup of excess cerebrospinal fluid in the ventricles of the brain. Ventricles are fluid filled areas in the brain. Cerebrospinal fluid is a body fluid that is found in the brain and in the spine.

What is a shunt and what does it do? A shunt is a long, flexible, plastic tube that drains fluid from the brain to another body compartment, commonly the peritoneum- in the belly.



What are the potential hazards of shunts?

- **Cerebral shunts (also called brain shunts) are likely to develop clogs and malfunctions.** If the shunt is malfunctioning, it will not drain the cerebrospinal fluid and can cause an increase in brain pressure.
- **Approximately fifty percent of all cerebral shunts will fail within the first year of placement**
- **Identifying shunt malfunction quickly is important because shunt failure can result in permanent neurological damage or death**



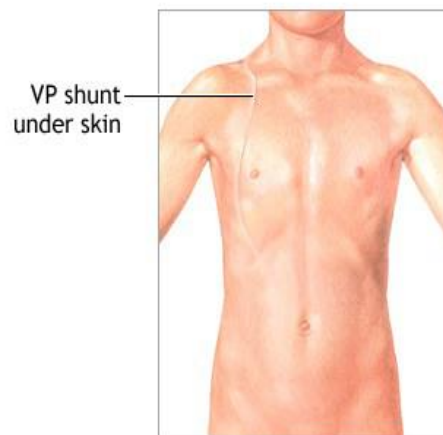
Virginia Department of Behavioral Health & Developmental Services

Care Responsibilities and Management of People with Shunts:

- **Wash hands before and after touching the shunt site**
- **Monitor the skin integrity over the shunt site to make sure the skin is undamaged** - look for areas of skin breakdown/damage on the head and along the shunt site
- **Monitor vital signs** (fever typically occurs in the morning) - Report fevers over 100.5
- **Monitor for headache**
- **Monitor for a change in behavior** (lethargy, drowsiness irritability, confusion)
- **Monitor the individual's intake of food for a decrease in appetite**
- **Monitor the individual for a sudden change in vision** (difficulty focusing, double vision, downward gaze)
- **Monitor the individual for a sudden change in gait/how the individual is walking** (shuffling, dizziness, unsteadiness)
- **Monitor individual for vomiting** (vomiting can be a sign of increased intracranial pressure)
- **Monitor for fluid leak from the site where the shunt is inserted**

A person with a shunt should wear a helmet for activities that may cause head injury.

Discourage individuals who have shunts from wearing purses or backpacks on the side where the shunt tubing passes down the neck.



ADAM.

Keep devices known to contain magnets away from the immediate valve implant area. Devices with magnets can change valve setting. Radiation generated by security scanners, metal detectors, microwave ovens, mobile telephones, high voltage lines, and transformers should not affect the performance of the valve.

Check valve settings after an MRI. Notify the individual's clinician to make sure the valve setting is correct after a magnetic resonance imaging (MRI) procedure.

Monitor the individual's bowel movements for constipation. Constipation can cause the shunt to malfunction. Increased abdominal pressure (caused by constipation) may cause a decrease in the



Virginia Department of Behavioral Health & Developmental Services

cerebrospinal fluid that drains through the shunt, which in turn will cause the size of the ventricles in the brain to increase. Notify a nurse if constipation occurs.

Regular neurosurgical follow up is critical. Individuals with a shunt need regular neurosurgical follow-up throughout their lives. Make sure the individual with a shunt has regularly scheduled follow up appointments with the physician who is monitoring the shunt.

Flag the chart. Highlight in the individual's chart the name and type of shunt, and the emergency contact information for the physician who placed the shunt and/or the physician who is monitoring the individual's shunt.

Keep the records of all brain scans. Maintain a record of all previous brain scans (including MRI and CT scans) including the reports and the actual scans, if available.

Sources:

Bragg, Edwards-Beckett, J., Eckle, N., Principe, K., & Terry, D. (1994). Ventriculoperitoneal shunt dysfunction and constipation: a chart review. *Journal of Neuroscience Nursing*, 26(5), 265-269.

Iskandar, B. J., McLaughlin, C., Mapstone, T. B., Grabb, P. A., & Oakes, W. J. (1998). Pitfalls in the diagnosis of ventricular shunt dysfunction: radiology reports and ventricular size. *Pediatrics*, 101(6), 1031-1036.

Kirkpatrick, M., Engleman, H., & Minns, R. A. (1989). Symptoms and signs of progressive hydrocephalus. *Archives of disease in childhood*, 64(1), 124-128.

Neumiller, J. J. (2013). Review of the Treatment & Management of Hydrocephalus. *US Pharm*, 3, 20.

Rekate, H. L., & Wallace, D. (2003). Lumboperitoneal shunts in children. *Pediatric neurosurgery*, 38(1), 41-46.

Neumiller, J. J. (2013). Review of the Treatment & Management of Hydrocephalus. *US Pharm*, 3, 20

Updated: October 2016